

Abnormal detached heads: A characteristic morphological abnormality in spermatozoa of Holstein Friesian x Sahiwal crossbred bulls

H C PANT¹, A K MITTAU, R KASIRAJI, J H PRABHAKAR⁴ and A K MISRN

Sabarmati Ashram Gausha/a, Lali, Kheda, Gujarat 387120 India Received: 5

February 2001; Accepted: 15 October 2001

Key words: Bulls, Detached heads, Sperm morphology

A small percentage of free, loose or detached normal heads are commonly found in the semen of normal fertile bulls. In our laboratory, the incidence of free normal heads in ejaculates from normal Jersey, Holstein Friesian and their crossbred bulls ranges from 0.4 to 5.4% (Pant 2000). This communication describes a high incidence of abnormal detached heads in a sizeable proportion of Holstein Friesian x Sahiwal crossbred bulls.

HF x Sahiwal crossbred bulls (21) produced in the ONBS project of SAG, Bidaj, were used for this study. Their semen

men of 6 bulls showed a high incidence of detached heads and data of 5 bulls which were followed for 4 to 8 weeks are shown in Table I. The bulls were not vaccinated during this period.

The overall incidence of detached heads ranged between 32.7 and 81.6% (Table 1). Additionally, majority of loose heads were of abnormal morphology characterized by abnormal shape, knobbed, ruffled, swollen or lost acrosome, vacuolation and small size (Figs 1-3).

Others have reported, the decapitate sperm defect in Guern-

Table I. Percent incidence of loose heads in 5 crossbred bulls (Holstein Friesian x Sahiwal) over a period of 4 to 8 weeks

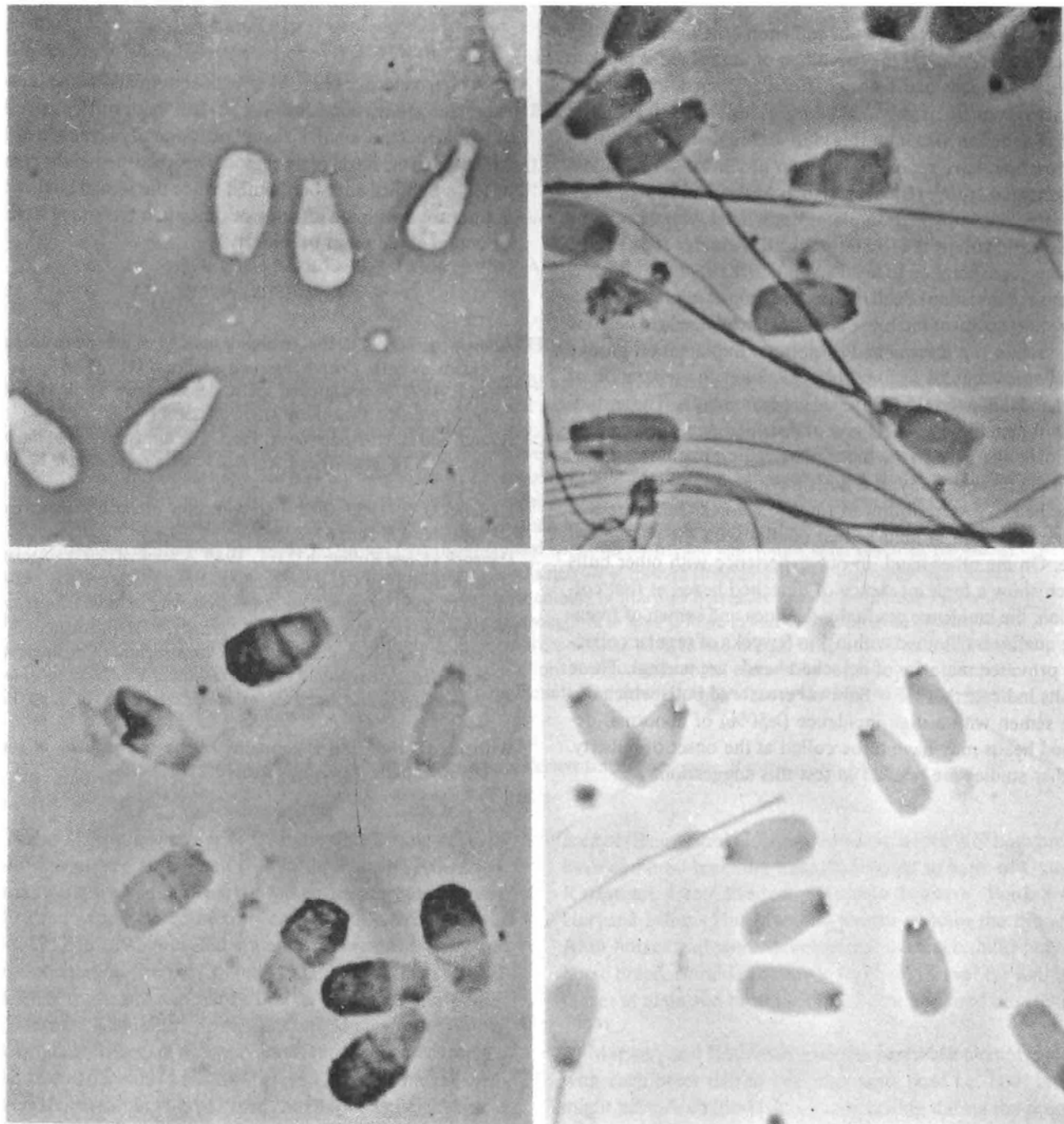
Bull No.	Type of loose heads	Weeks							
		2	3	4	5	6	7	8	
	Normal	15.0	20.0	8.0	27.0	13.8	25.0	27.3	9.6
	Abnormal	55.0	61.6	57.3	33.0	51.7	53.0	48.3	66.4
	Total	70.0	81.6	65.3	60.0	65.5	78.0	75.6	76.0
2	Normal	27.0	20.5	23.6	14.7	22.5	14.3		
	Abnormal	35.5	30.0	20.5	26.1	30.6	40.8		
	Total	62.5	50.5	44.1	40.8	53.1	55.1		
3	Normal	2.4	4.4	2.7	2.9	1.0			
	Abnormal	71.5	65.4	71.1	71.9	69.4			
	Total	73.9	69.8	73.8	74.8	70.4			
4	Normal	1.5	2.2	2.3	1.6	2.5	1.0	2.4	
	Abnormal	31.2	56.4	47.4	38.6	46.9	45.4	40.0	
	Total	32.7	58.6	49.7	40.2	49.4	46.4	42.4	
5	Normal	3.2	1.5	1.1	8.9				
	Abnormal	56.0	61.4	66.1	43.3				
	Total	59.2	62.9	67.2	2.2				

was collected weekly in artificial vagina. It was evaluated for volume, concentration, progressive motility and morphology employing standard laboratory procedures (Pant 2000). Se-

Present address: ¹Advisor, ²Manager, ³Deputy General Manager (Technical), ⁴General Manager.

Associate Professor, College of Veterinary Sciences, GBPUAT, Pantnagar 263 145.

sey (Hancock and Rollinson 1949, Hancock 1955, Alun-Jones 1962), Hereford (Williams 1965, Blom 1977) and Swedish Red and White breed (Settergren and Nicander 1968). According to BJorn (1977), in the Hereford bulls, the 3 main characteristics of semen with the decapitate sperm defect were: (i) separation of heads and tails in 80-100% of sperm; (ii) active movement in a high percentage of loose tails; and (iii) a proximal



Figs 1-4. 1. Eosin-nigrosin stained smear showing abnormal detached heads. 2. Rose Bengal-stained smear showing abnormal detached heads. 3. Giemsa-stained smear showing abnormal detached heads with lost and ruffled acrosomes. 4. Feulgen's-stained smear showing vacuoles in the basal plate of a few detached heads.

bending of the midpiece around the cytoplasmic droplet often seen in the free tails. However, Williams (1965) did not report the motile free tails in Hereford bulls. In Guernsey bulls, almost all intact sperm had neck droplets and almost all free tails had distal droplets. In all these studies, majority of loose heads were morphologically normal and only a few abnormal head shapes were seen. Contrary to these observations, in our study with crossbred bulls the incidence of loose heads was

<80% and majority of loose heads were morphologically abnormal (Figs 1-3). However, we also observed that a sizeable percentage of loose tails showed active movement and in a few tails the midpiece was curled around a cytoplasmic droplet. Among the morphological abnormalities of loose heads, knobbed, ruffled, swollen and lost acrosome were more common.

In our study, Feulgen staining of ejaculates from 1 bull

revealed a very interesting phenomenon- the basal plate, the structure that connects the capitulum of the tail to the head, in some loose heads had 1 or occasionally 2 vacuoles (Fig. 4). We are not aware of any such previous report. Earlier studies with European or Scandinavian breeds, using electron microscopy, have reported either an absent or very shallow implantation groove (Biom and Birch Anderson 1965) or small and irregular implantation plates associated with an oblique implantation of the tail (Settergren and Nicander 1968) as the reasons for separation of head and tail in the caput epididymis because of initiation of cell motion and droplet migration. Electron microscopy of the loose abnormal head needs to be done to ascertain if a narrow 'and/or oblique implantation groove alongwith vacuoles in basal plate account for separation of head and tail in the HF x Sahiwal crossbred bulls. These studies will also indicate the stage of spermatogenesis when the vacuoles observed in the basal plate region begin to appear.

In the present study of 6 bulls having a high incidence of loose heads, 5 were followed for 4 to 8 weeks but there was no improvement in their semen quality with the passage of time. On the other hand, in our experience with other bulls which show a high incidence of detached heads at first collection, the incidence gradually declines and semen of freezable quality is obtained within 4 to 6 weeks of regular collection provided majority of detached heads are normal. These results indicate that HF x Sahiwal crossbred bulls which donate semen with a high incidence (>50%) of abnormal detached heads may have to be culled at the onset of puberty. Further studies are needed to test this suggestion.

SUMMARY

A high incidence (32.7-81.6%) of abnormal detached heads, characterized by abnormal shape, knobbed, ruffled, swollen or lost acrosome, small size and occasionally presence of 1-2 vacuoles in the basal plate region, was recorded in the semen of HF x Sahiwal crossbred bulls. Since the semen quality did not improve with the passage of time such bulls may have to be culled at the onset of puberty.

REFERENCES

- Alun-Jones W. 1962. Abnormal morphology of the spermatozoa in Guernsey bulls. *British Veterinary Journal* 18: 257-61.
- Blom E. 1977. A decapitated sperm defect in two sterile Hereford bulls. *Nordisk Veterinary Medicine* 29: 119-23.
- Blom E and Birch-Andersen A. 1965. The ultrastructure of the bull sperm. 2. The sperm head. *Nordisk Veterinary Medicine* 17: 193-212.
- Hancock J L. 1955. The disintegration of bull spermatozoa. *Veterinary Record* 67: 825-26.
- Hancock J Land Rollinson O H L. 1949. A seminal defect associated with sterility of Guernsey bulls. *Veterinary Record* 61: 742-43.
- Pant H C. 2000. *Morphological Abnormalities in Buffalo and Cattle Spermatozoa: Relation to Bull Fertility*. NODB, Anand.
- Settergren I and Nicander L. 1968. Ultrastructure of disintegrated bull sperm. *Proceeding 6th International Congress in Animal Reproduction and Artificial Insemination*. Paris. Vol. I, pp. 191-94.
- Williams G. 1965. An abnormality of the spermatozoa of some Hereford bulls. *Veterinary Record* 77: 1204-06.